

Case Report

Management of hydrocoele through homoeopathy: A case report

Sangeeta Jain¹, Shishir Mathur²

¹Department of Anatomy, ²Department of Physiology and Biochemistry, Dr. M.P.K. Homoeopathic Medical College, Hospital and Research Centre (A Constituent College of Homoeopathy University), Jaipur, Rajasthan, India.

*Corresponding author:

Dr. Sangeeta Jain,
Department of Anatomy,
Dr. M.P.K. Homoeopathic
Medical College, Hospital and
Research Centre (A Constituent
College of Homoeopathy
University), 172, G-2, Gayatri
Nagar-B, Maharani Farm,
Durgapura, Jaipur - 302 018,
Rajasthan, India.
arihanthomoeo25@gmail.com

Received : 20 June 2020
Accepted : 20 November 2020
Published : 24 December 2020

DOI
10.25259/JISH_25_2020

Quick Response Code:



ABSTRACT

An abnormal collection of serous fluid within the tunica vaginalis or some part of processus vaginalis surrounding the testicles is termed as *Hydrocoele*. In many newborn cases, hydrocoele disappears on its own within 1st year of birth; if it does not disappear, then it needs to be surgically removed, but the procedure has its own risks. Homoeopathy assures the dissolution of fluid and prevents the risks of surgery. A 2-year-old boy with a scrotal enlargement (left-sided; volume 35 mm × 16 mm) presented at the outpatient department of Dr. MPK Homoeopathic Hospital, Jaipur, Rajasthan. Based on the presenting totality and pathological diagnosis, *Pulsatilla* 200 and an intercurrent remedy *Rhododendron* 200 were prescribed. The scrotal enlargement disappeared within 3 months, which proved the usefulness of homeopathic management in the case of hydrocoele.

Keywords: Hydrocoele, Homoeopathy, *Pulsatilla nigricans*, *Rhododendron*

INTRODUCTION

A hydrocoele is a fluid collection that may occur anywhere along the path of testicular descent.^[1] Hydrocoele occurs when there is an abnormal accumulation of serous fluid between the parietal and visceral layers of the tunica vaginalis that surround the testicle;^[2] it is usually caused by incomplete or late closure of the processus vaginalis.^[3] In adults and adolescents, hydrocoele is an acquired condition,^[2] occurring due to venous and lymphatic obstruction caused by infection or trauma.^[4] The occurrence rate of hydrocoele is 1% in adult males, mostly over the age of forty, and 4.7% in neonates.^[5] In a majority of neonates, hydrocoele subsides spontaneously within a year; if this does not happen, treatment is required, usually in the form of surgery.^[6] Homoeopathic treatment focuses on the patient as a person, as well as their clinical diagnosis.^[7] Homoeopathic medicines are selected after a full individualizing examination and case analysis, which take into account several factors, including the medical history of the patient and their parents and the patient's physical and mental constitution. A miasmatic tendency (predisposition/susceptibility) is also often taken into account.^[8]

CASE REPORT

Chief complaint

Enlargement of the left side of the scrotum for the past 7 months.

This is an open-access article distributed under the terms of the Creative Commons Attribution-Non Commercial-Share Alike 4.0 License, which allows others to remix, tweak, and build upon the work non-commercially, as long as the author is credited and the new creations are licensed under the identical terms.

©2020 Published by Scientific Scholar on behalf of Journal of Integrated Standardized Homoeopathy

History of presenting illness

A 2-year-old male child reported to the outpatient department of the Dr. MPK Homoeopathic Hospital on August 23, 2019, with the complaint of unilateral enlargement of the scrotum (the left side was larger than right) with slight pain on pressure. The child's parents had observed slight enlargement of the scrotum 7 months prior, which had gradually increased in size. Initially, there was no pain with a very minor difference in the size of both sides of the scrotum; the patient's parents did not think anything which was wrong. They consulted a urologist when the enlargement became prominent. The urologist advised surgery, but the parents refused surgery and consulted us for homeopathic intervention.

Patient as a person

The child was very restless, changing his position very frequently, even in his mother's lap. He was irritable; he wanted to be carried sometimes and left alone sometimes. He demanded many things during the case taking, and when given those, he threw them away. His mother stated that he does not keep his things in place; he is very chaotic. She also informed us that he was very fond of eating potatoes and disliked oily and sweet items, such as halwa. He had an abnormal craving for licking soil from the doors and lime from the walls. His appetite and thirst were normal. He also wet the bed 3–4 times a week. He had profuse perspiration on his face, especially the forehead and nose.

Clinical examination

1. Inspection: Left side of the scrotum swollen; negative impulse on coughing
2. Palpation: Mild tenderness on pressure; positive fluctuation with no reduction
3. Transillumination test: Positive.

Diagnosis

1. Clinical: Primary hydrocele
2. The ultrasound report [Figure 1]: Showing left hydrocele with a volume of 35 mm × 16 mm (dated June 10, 2019).

Medical and personal history

Negative for any infection related to the urinary system.

Family history

The mother had tubal blockage and was treated for that before the patient's birth.

Case analysis

As the patient had very peculiar mental and physical symptoms and some peculiar pathological symptoms, he was analyzed accordingly for framing the totality of symptoms [Table 1].

Selection of repertory and repertorization

Considering the above symptomatology, synthesis repertory was preferred, and using RADAR 10.0 software, systemic repertorization was done.^[9,10] The repertorization chart is given in [Figure 2].

Prescription with follow-ups

The repertorial result showed that *Pulsatilla* covered 8 out of 10 symptoms with high gradings [Table 2]. The

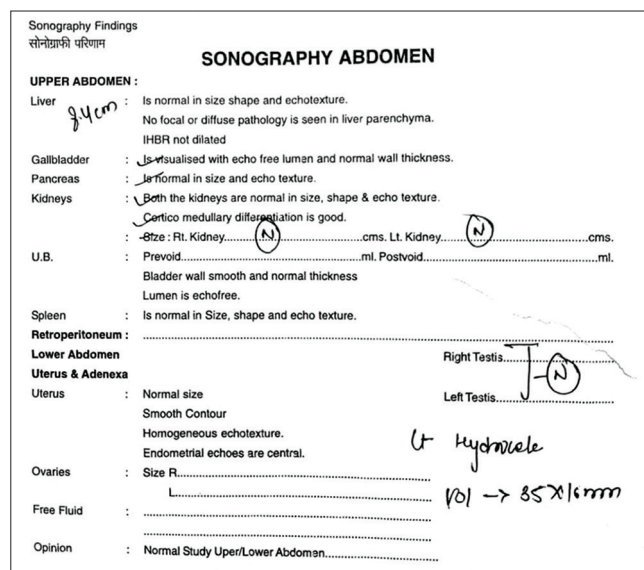


Figure 1: Pre-treatment USG report.

Table 1: Analysis and evaluation of the case.

Mentals	Physical symptoms	Particular/ pathological symptoms	Common symptoms
1. Restlessness (++)	1. Abnormal cravings for soil and lime (+)	1. Profuse perspiration on face (++)	1. Bedwetting (+)
2. Chaotic behaviour (++)	2. Desire for potatoes (+++)	2. Scrotal swelling left side (++)	
3. Changeability in nature (+++)	3. Aversion for fatty food (+++)		
4. Irritability (+++)			

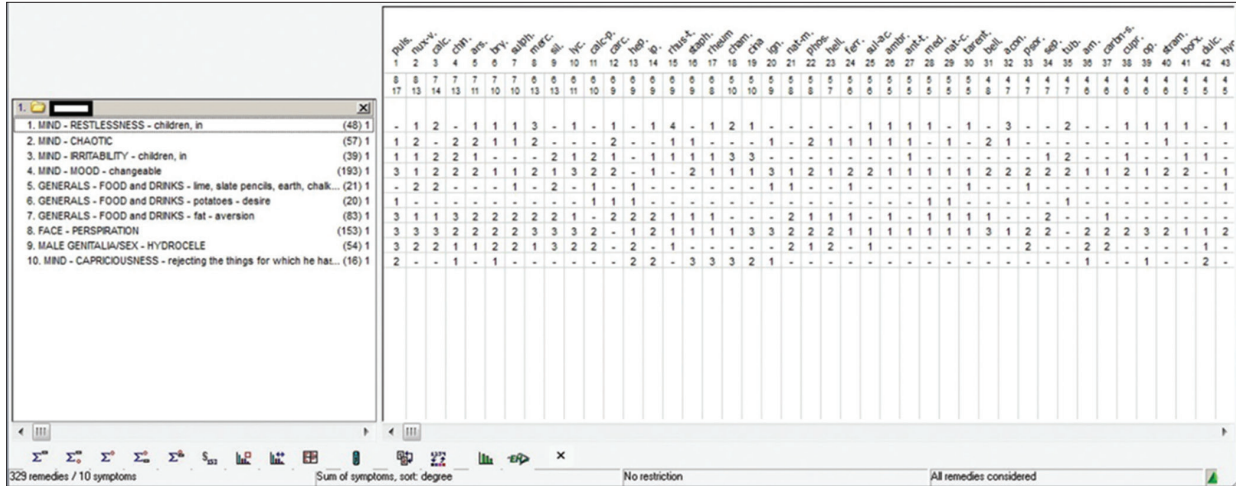


Figure 2: Repertorization chart.

Table 2: Follow-up chart.

Date	Changes in symptomatology	Prescription
August 23, 2019	First visit of the patient; case taking and repertorization done; slight tenderness on palpation and transillumination positive; and USG report: left hydrocoele (vol: 35 mm × 16 mm)	Pulsatilla 200/stat; Sac lac 30/TDS for 15 days
September 8, 2019	Better in tenderness but no change in the size of scrotum; patient's behavior- slightly calmer	Pulsatilla 200/stat; Sac lac 30/TDS for 21 days
October 2, 2019	No tenderness; but reduction in size of scrotum was not marked. Calm behavior of patient; diet pattern also changed; now relishes fatty food too	Rhododendron 200/stat; Sac lac 30/TDS for 7 days
October 10, 2019	Scrotal size slightly reduced; Rest all the better than previous	Pulsatilla 200/stat; Sac lac 30/TDS for 21 days
November 2, 2019	Marked reduction in size of the scrotum. Rest all as previous	Rhododendron 200/stat; Sac lac 30/TDS for 7 days
November 10, 19	Patient asymptomatic; advised for USG of scrotum	Pulsatilla 200/stat; Sac lac 30/TDS for 7 days
November 17, 19	USG report: normal scrotal sac; transillumination negative; patient's behavior becomes mild; no bedwetting for the past 2 weeks	Sac lac 30/TDS for 30 days

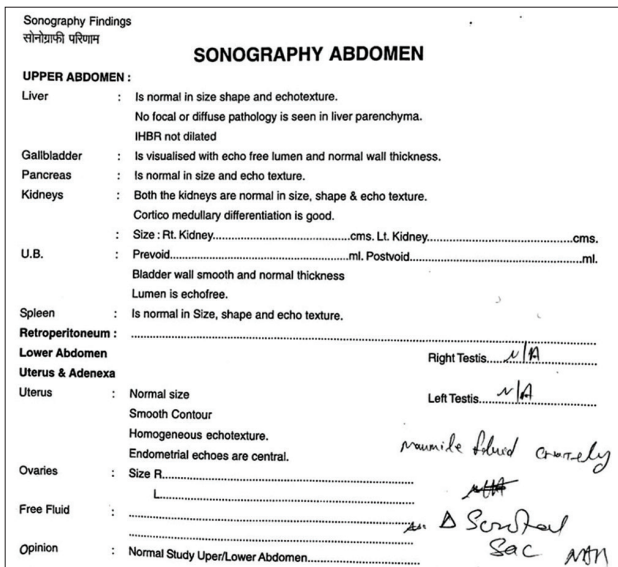


Figure 3: Post-treatment USG report.

changeability of mood with irritability^[11] and aversion for fatty food^[12] is keynotes of Pulsatilla. Hydrocoele (pathological symptom) and involuntary urination in the night (common symptom) are also covered by Pulsatilla.^[13] Pulsatilla also covered the miasmatic predominance of the patient that is toward sycotic (history of tubal blockage in mother). Therefore, according to the symptom totality and miasmatic predominance, the child was prescribed Pulsatilla 200 one dose stat followed by Sac lac 30 thrice a day (TDS). The dose was repeated weekly basis in the first month and then every 15 days till the 3rd month. Rhododendron 200 was also prescribed as an intercurrent^[14] remedy, as after more than 1 month, the pathological symptom (left hydrocoele)^[15] had not resolved. The parents were advised not to allow the patient to perform any strenuous physical activities as it could injure the swollen testis and give the patient scrotal support undergarments. After 3 months of treatment, an ultrasonography of the scrotum was advised (report on November 16, 2019) [Figure 3], which showed

a normal scrotal sac. The transillumination test was also found negative, and there was no tenderness on palpation. The patient's behavior had also become mild, as informed by his mother. The patient was asymptomatic.

DISCUSSION AND CONCLUSION

As the patient was a 2-year-old child, collection of symptoms was not easy, and totality with individualization was not possible. Moreover, hydrocoele does not have many symptoms. Therefore, with the limited symptomatology, the present case identifies the usefulness of homeopathic medicines in the management of hydrocele in children. Pulsatilla 200 corrected the patient's behavior and personality as well as the left hydrocoele with the intercurrent use of rhododendron 200 within 3 months. In a similar study by Basu,^[16] a right-sided hydrocoele was resolved by administering Rhus tox selected according to presenting individualization. This case also signifies the importance of homoeopathy in the management of hydrocoele.

Acknowledgment

We acknowledge Ms. Roshan Choudhary and Ms. Nalini Tiwari (Interns; Dr.MPK Homoeopathic Medical College, Hospital and Research Centre, Constituent College of Homoeopathy University), who helped a lot in working out the case.

Declaration of patient consent

Patient's consent not required as patients identity is not disclosed or compromised.

Financial support and sponsorship

Nil.

Conflicts of interest

There are no conflicts of interest.

REFERENCES

- Wallace NG, Amaya M. Normal and developmental variations in the anogenital examination of children. In: Jenny C, editor. Child Abuse and Neglect. Rhode Island: Saunders; 2010. p. 69-82. Available from: <http://www.books.google.co.in/books?id=BKILM5KWFkWC&pg=PA80&lpg=PA80&dq=> [Last accessed on 2020 Mar 16].
- Parks K, Leung L. Recurrent hydrocele. *J Fam Med Prim Care* 2013;2:109-10.
- Caterino S, Lorenzon L, Cavallini M, Cavaniglia D, Ferro F. Epididymal testicular fusion anomalies in cryptorchidism are associated with proximal location of the undescended testis and with a widely patent processus vaginalis. *J Anat* 2014;225:473-8.
- Cimador M, Castagnetti M, De-Grazia E. Management of hydrocele in adolescent patients. *Nat Rev Urol* 2010;7:379-85.
- Osifo OD, Osaigbovo EO. Congenital hydrocele: Prevalence and outcome among male children who underwent neonatal circumcision in Benin City, Nigeria. *J Pediatr Urol* 2008;4:178-82.
- Hydrocele in Children; 2020. Available from: <https://www.urmc.rochester.edu/encyclopedia/content.aspx?contenttypeid=90&contentid=p03090>. [Last accessed on 2020 May 09].
- Kishore J. In: Hering C, editor. The Guiding Symptoms of our Material Medica. New Delhi: B Jain Publishers Pvt. Ltd.; 1971.
- Bhatia M. Homoeopathic Medicine for Hydrocele; 2009 Available from: <https://www.hpathy.com/cause-symptoms-treatment/hydrocoele>. [Last accessed on 2020 Jun 03].
- Frederik S, editor. Synthesis-Repertorium Homoeopathicum Syntheticum. London: Homeopathic Book Publishers; 1993. p.17.
- RADAR Computer Program. Version 10.0. London: Archibel Homoeopathic Software; 2018.
- Murphy R. Lotus Materia Medica. 2nd ed. New Delhi: B Jain Publishers Pvt., Ltd.; 2004.
- Boericke W. Homoeopathic Material Medica. New Delhi: B Jain Publishers Pvt., Ltd.; 2004.
- Clarke JH. The Dictionary of Practical Materia Medica. London: The Homoeopathic Publishing Company; 1909.
- Sarkar BK. Organon of Medicine by Samuel Hahnemann. 5th ed. New Delhi: Birla Publications Pvt., Ltd.; 2005.
- Sharma V. Top 10 Homoeopathic Medicines for Hydrocele; 2020 Available from: <https://www.drhomeo.com/homeopathic-treatment/homeopathic-medicines-for-hydrocele>. [Last accessed on 2020 July 25].
- Basu N. A Case of Hydrocele. Clinical and Experimental Homoeopathy. Vol. 4. 2017. Available from: http://www.journal.sukulhomeopathy.com/gallery/Nilanjana_17P.pdf. [Last accessed on 2020 May 09].

How to cite this article: Jain S, Mathur S. Management of hydrocoele through homoeopathy: A case report. *J Intgr Stand Homoeopathy* 2020;3(3):75-8.