

Case Report

An evidence-based case of bilateral nephrolithiasis treated with individualised homoeopathic medicine: A case report

Nabanita Debnath¹, Kapil Das²

¹Department of Practice of Medicine, National Institute of Homoeopathy, Kolkata, West Bengal, ²Senior Research Fellow, Regional Research Institute of Homoeopathy, Central Council for Research in Homoeopathy, Agartala, Tripura, India.

***Corresponding author:**

Dr. Kapil Das, M D (Hom.)
Regional Research Institute of
Homoeopathy, Agartala, Under
Central Council for Research
in Homoeopathy, Ministry of
AYUSH, Agartala, Tripura,
India.

kapildas11993@gmail.com

Received: 07 November 2023
Accepted: 23 October 2024
Epub Ahead of Print: 23 December 2024
Published:

DOI
[10.25259/JISH_70_2023](https://doi.org/10.25259/JISH_70_2023)

Quick Response Code:



ABSTRACT

Nephrolithiasis, or renal calculi, is a painful and common urinary disorder affecting millions worldwide. Conventional treatments primarily focus on pain management and calculus removal, but concerns about recurrence have led many patients to seek alternative therapies. Homoeopathy, a holistic medical system, offers an intriguing approach to managing nephrolithiasis. A 35-year-old patient presented with bilateral flank pain radiating up to the groin with an ultrasonography report of non-obstructive bilateral renal calculi. He was treated effectively with the homoeopathic medicine *Thuja*, which was selected according to case totality. This case shows the efficacy of homoeopathic medicines in addressing and expelling bilateral renal calculi. A large-scale randomised trial is recommended to assess the efficacy of individualised homoeopathic treatment.

Keywords: Nephrolithiasis, Renal calculi, Homoeopathy, *Thuja*, Case report

INTRODUCTION

Renal calculi are amongst the most prevalent urological issues.^[1] Approximately 2% of the population develops renal calculi at some point in their life, with a male-female ratio of 2:1. The highest occurrence is seen in people in their 20s and 30s.^[2] Urolithiasis occurs when urine solutes crystallise to form calculi due to factors such as low urine volume, anatomic features causing urinary stasis, dietary factors, infections, acidosis, medications, or genetic factors such as cystinuria. The main cause is inadequate hydration and low urine volume. Other common factors include hypercalciuria, hyperoxaluria, hyperuricosuria and hypocitraturia.^[3]

Renal calculi have different types, including calcium, struvite, uric acid, and cystine. Amongst these, calcium is the most common type, with a higher recurrence rate.^[4] Calculi can be asymptomatic or cause haematuria; moreover, when they pass, they may cause severe pain radiating from the loin to the groin, accompanied by nausea, vomiting, and light-headedness.

Most renal calculi are small enough to pass spontaneously. However, in case of larger calculi (6–7 mm or larger), extracorporeal shock wave lithotripsy or surgery may be required.^[5] Depending on the circumstances, a small calculus (<5 mm) can take 4–6 weeks to pass. However, if it fails to pass spontaneously, the physician can provide appropriate medication, such as an

alpha-blocker and calcium channel blocker.^[6] Radiography of the kidney-ureter-bladder region detects 90% of radio-opaque renal calculi, while abdominal ultrasonography (USG) can find radiolucent ones. Computed tomography helps locate small missed ureter calculi.^[7]

Homoeopathy, which takes a holistic approach to treating the individual as a whole, can play an important role in properly managing renal calculi. According to studies, the disintegration or evacuation of calculi can be positively influenced by homoeopathic treatment. The Central Council for Research in Homoeopathy carried out a prospective, multi-centric observational study^[8] to determine the role of homoeopathic therapy in urolithiasis, in which 106 of 220 cases reported the expulsion of calculi. The individualised homoeopathic medicines (IHMs) reported to be effective in this study included *Lycopodium clavatum*, *Sulphur*, *Pulsatilla nigricans*, *Nux vomica*, and *Cantharis*.

CASE REPORT

Patient information

A 35-year-old man sought medical attention at the National Institute of Homoeopathy, Kolkata, on 6th December 2021; presented with a complaint of flank pain on both sides that had been persisting for 6 months along with a USG report of non-obstructive bilateral nephrolithiasis. The pain was more pronounced on the left side and extended up to the groin on both sides. The pain was exacerbated before urination and relieved by movement.

History of presenting complaints

The patient was asymptomatic 6 months prior; then, he began experiencing flank pain on the left side, which gradually progressed to both sides. The patient had not sought any treatment for the past few months since the symptoms began. Despite maintaining a healthy diet and consuming plenty of water, his complaints persisted for 6 months, pushing him to seek medical attention.

Personal history

The patient had renal calculi 5 years prior and had been successfully treated with homoeopathic medication for the same.

Family history

No significant family history was found.

Physical generals

The patient has a good appetite but is easily satiated. He craves extra salt and raw onion; he prefers cold food. His

thirst is moderate. He experiences a burning sensation during urination; the urine has a strong odour. His stool is often offensive. His perspiration has an offensive odour, more while sleeping. His thermal sensitivity was chilly.

Mental generals

The patient was irritable, easily angered, and desired to work according to his preferences.

Clinical examinations

The blood pressure and pulse were 120/80 mmHg and 77 beats/min, respectively. No significant abnormalities were found on further general examination.

Diagnostic assessment

Ancillary investigation of USG of the whole abdomen indicates multiple small calculi with varying sizes (2.4–3.3 mm) in both kidneys and grade I hepatic steatosis [Figure 1].

This case was diagnosed as bilateral non-obstructive nephrolithiasis based on the investigation results. The diagnosis was coded GB70.0 according to the International Classification of Diseases, 11th Revision classification; it stands for calculus of the kidney.^[9]

Analysis of the case and repertorial result

After conducting a thorough case-taking and analysing all the mental, physical, and particular symptoms, each symptom was evaluated based on its significance [Table 1].

In this case, repertorisation was carried out using the Zomeo computer software, using Kent Repertory.^[10] After repertorisation, the top-ranked medicines were *Thuja* (17/8), *Phosphorus* (16/7), *Lycopodium* (15/6), and Nitric acid (15/6). The repertorial result is shown in Figure 2.

Therapeutic intervention

Considering the repertorial totality and consultation with Materia Medica, *Thuja* 0/1 was given on alternative days for 30 days. He was advised to take plenty of water and undergo a urine examination.

Basis of prescription

The patient was irritable, his appetite was good but easily satiated. He has a marked desire for raw onion and prefers cold food. He had a burning sensation during urination with a strong odour. His perspiration has an offensive odour, and his thermal relation is chilly. On repertorial analysis, *Thuja* stood at the number one position.

Table 1: Analysis and evaluation.

Characteristic Mental Generals	(i) Irritability.
Characteristic Physical Generals	(ii) Appetite – easily satiate. (iii) Desire – raw onion, salty and cold food. (iv) Perspiration – offensive in odour. (v) Urination had a strong odour. (vi) Thermal relation – chilly.
Particulars	(vii) Burning sensation during urination. (viii) Pain in both lumber regions extending to the groin. (ix) Pain < before burning urination and > by motion.

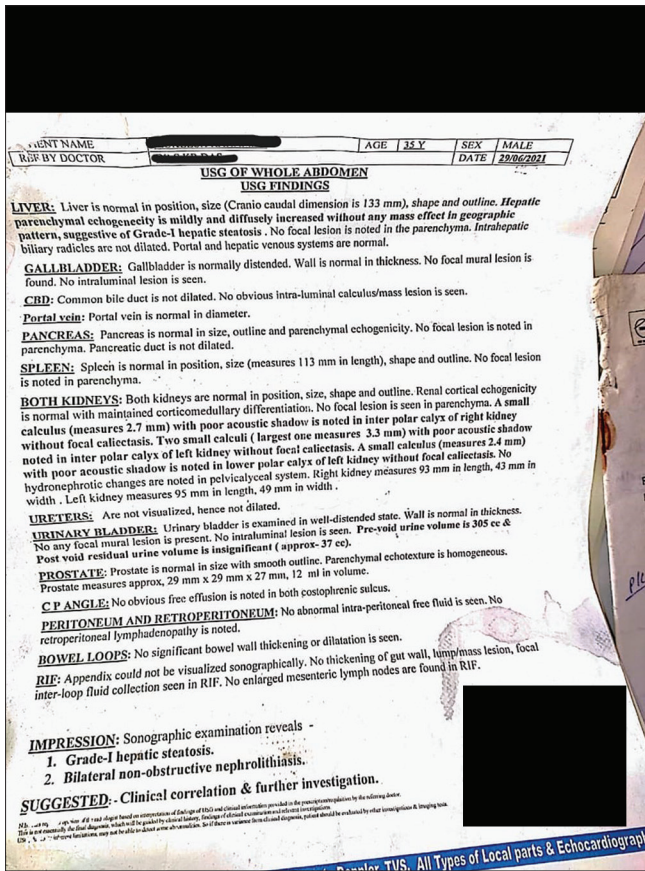


Figure 1: Ultrasonography report before treatment.

Remedy	Thu	Phos	Lyc	Nit-ac	Sulph	Nat-m	Calc-y
Totally	17	16	15	15	14	11	11
Symptoms Covered	8	7	6	6	6	6	5
Kingdom	3	3	3	3	3	3	3
[Kent] [Mind]IRRITABILITY (SEE ANGER): (24)	3	3	3	3	3	3	3
[Kent] [Stomach]APPETITE:Easy satiety: (67)	2	2	3	1	2	2	2
[Kent] [Stomach]DESIRE:Cold Food: (14)	2	3	2			1	
[Kent] [Stomach]DESIRE:Salt things: (30)	1	3		2	1	3	3
[Kent] [Stomach]DESIRE:Onions,raw: (2)				2			
[Kent] [Perspiration]ODOUR:Offensive: (59)	3	2	3	3	3		2
[Kent] [Kidney]PAIN:Motion :Ameal: (1)							
[Kent] [Kidney]PAIN:Burning:Urination:Before: (2)	1						
[Kent] [Urine]BURNING (INCLUDES HOT): (156)	3	1	2	3	3	1	1
[Kent] [Urine]ODOUR:Strom: (53)	2	2	2	3	2	1	2

Figure 2: Repertorial sheet. The numbers in brackets indicate the number of medicines containing that particular symptom. The number 1/2/3 indicates grading of symptoms as per Kent’s repertory.

The 50 millesimal or LM potency was chosen to avoid undesirable aggravation, which is the main advantage of 50M potencies over CM.^[11]

Differentiating points

Phosphorus patients experience hunger even after eating, whereas in this case, the patient was easily satiated. *Lycopodium* patients desire sweet things and like to take food and drinks hot, whereas in this presented case, the patient desires salty and cold food. In comparison to *Thuja*, Nitric acid covers fewer symptoms and lacks important symptoms such as desire for raw onion and pain before urination.^[12]

Results

Following the use of the homoeopathic medication *Thuja* 0/1, the patient gradually improved. The drug was continued up to *Thuja* 0/5, with significant improvement in the manifesting symptoms. Follow-up is summarised in Table 2.

The overall duration of treatment with homoeopathic medication was 5 months (from December 06, 2021, to May 06, 2022). The patient was observed for an additional 6 months, and there was no indication of reappearance of symptoms during that period of time.

DISCUSSION

In this case, the patient had bilateral renal Calculi, that were successfully treated using homoeopathy. Although these calculi were non-obstructive or small sized, they had been bothering the patient for 6 months, prompting him to seek medical assistance. This case report followed the HOME-CASE guidelines^[13] for reporting the outcomes.

After a detailed case-taking and symptom analysis, *Thuja* Q1 was selected as the IHM for this case. Urine examination report at second visit (Jan 05, 2022) shows that RBC in urine was within normal limits [Figure 3]. After the initial prescription, the patient began to improve in his presenting issues within 1–2 months, and his complaints were fully

Table 2: Follow-up.

Date	Observation	Medicine
First visit December 06, 2021	<ul style="list-style-type: none"> • Baseline presenting complaints (signs and symptoms) 	<i>Thuja</i> 0/1/AD/30 days
Second visit January 05, 2022	<ul style="list-style-type: none"> • Pain in the right side of the flank was better, but on the left side, it was same • Burning during urine was occasionally present • Generals were good 	<i>Thuja</i> 0/2/AD/30 days
Third visit February 08, 2022	<ul style="list-style-type: none"> • The urine examination report shows that RBC in urine was within normal limits • Pain in both sides of flank was better • No episodes of burning during urine were observed • Generals were good 	<i>Thuja</i> 0/3/AD/30 days
Fourth visit March 09, 2022	<ul style="list-style-type: none"> • Patient was better • No episodes of burning during urine were observed • Generals were good 	<i>Thuja</i> 0/4/AD/30 days
Fifth visit April 06, 2022	<ul style="list-style-type: none"> • USG of the whole abdomen and a urine examination were suggested • No recurrence or worsening of his presenting complaints was observed further. • His USG investigation revealed no renal calculi or hepatic steatosis • The urine examination report shows no red blood cells in the urine 	<i>Thuja</i> 0/5/AD/30 days

USG: Ultrasonography, RBC: Red blood cell, AD: Alternate day

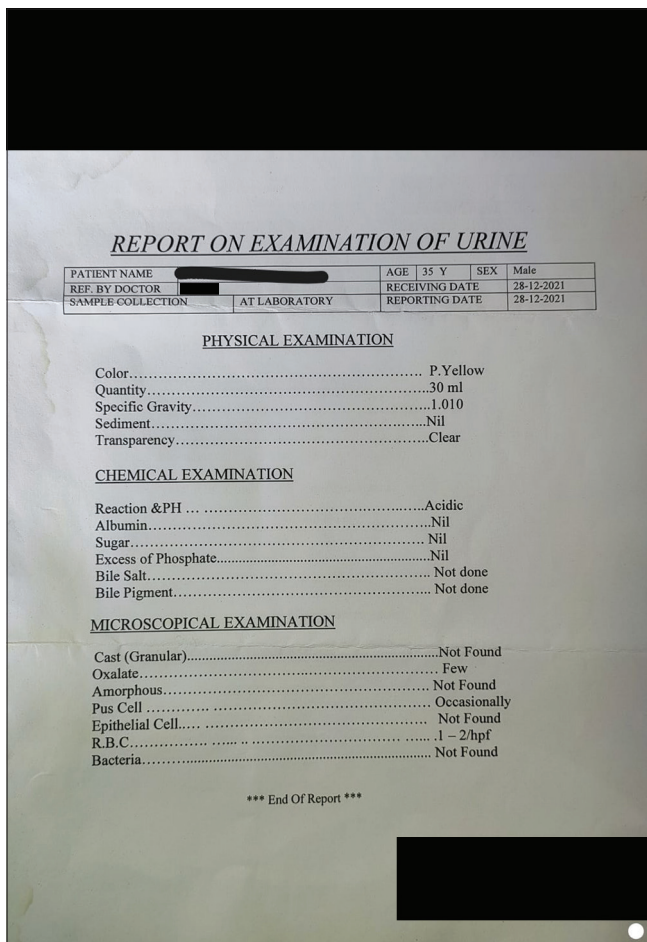


Figure 3: Urine report before treatment.

resolved after 4 months. *Thuja* up to 0/5 was maintained, and a USG of the entire abdomen was conducted on May 04, 2022,

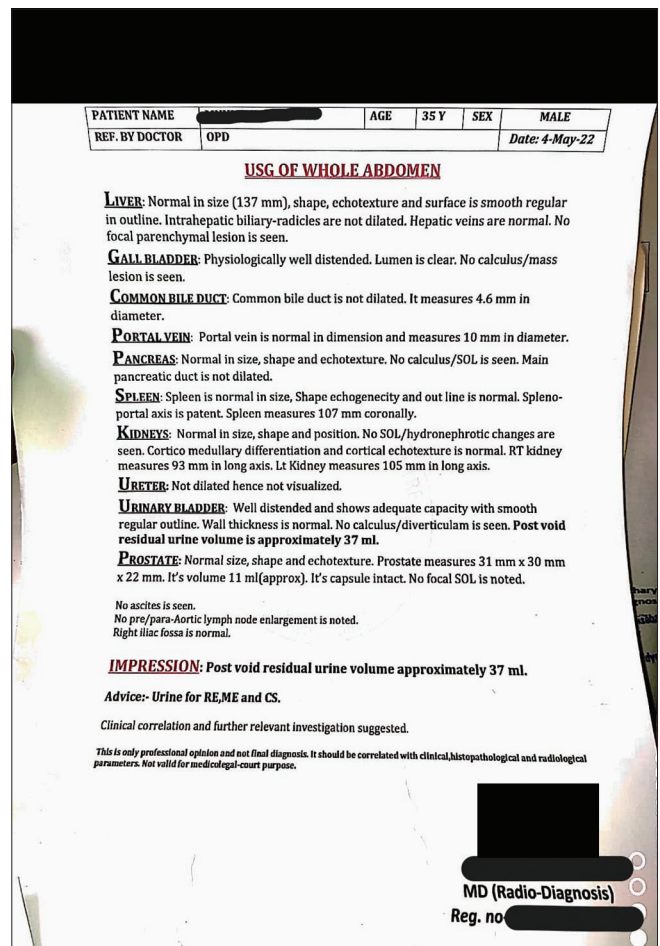


Figure 4: Ultrasonography report after treatment.

revealing no renal calculi. Hepatic steatosis or fatty liver also got resolved with the same IHM [Figure 4]. Urine examination

Table 3: Assessment done using the MONARCH inventory score.

S. No.	Domains	Yes	No	Not sure or N/A
1.	Was there an improvement in the main symptom or condition for which the homoeopathic medicine was prescribed?	+2	-	-
2.	Did the clinical improvement occur within a plausible time frame relative to the drug intake?	+1	-	-
3.	Was there a homoeopathic aggravation of symptoms?	-	0	-
4.	Did the effect encompass more than the main symptom or condition (i.e. were other symptoms, not related to the main presenting complaint, improved or changed)	+1	-	-
5.	Did overall well-being improve? (Suggest using a validated scale or mention about changes in physical, emotional, and behavioural elements)	+1	-	-
6A.	Direction of cure: Did some symptoms improve in the opposite order of the development of symptoms of the disease?	-	-	0
6B.	Direction of cure: Did at least one of the following aspects apply to the order of improvement of symptoms: <ul style="list-style-type: none"> • From organs of more importance to those of less importance? • From deeper to more superficial aspects of the individual? • From the top downwards? 	-	-	0
7.	Did 'old symptoms' (defined as non-seasonal and non-cyclical symptoms that were previously thought to have resolved) reappear temporarily during the course of improvement?	-	0	-
8.	Are there alternative causes (other than the medicine) that – with a high probability – could have produced the improvement? (Consider the known course of disease, other forms of treatment, and other clinically relevant interventions)	-	+1	-
9.	Was the health improvement confirmed by any objective evidence? (e.g., investigations and clinical examination)	+2	-	-
10.	Did repeat dosing, if conducted, create similar clinical improvement?	+1	-	-

MONARCH: Modified Naranjo Criteria for Homeopathy

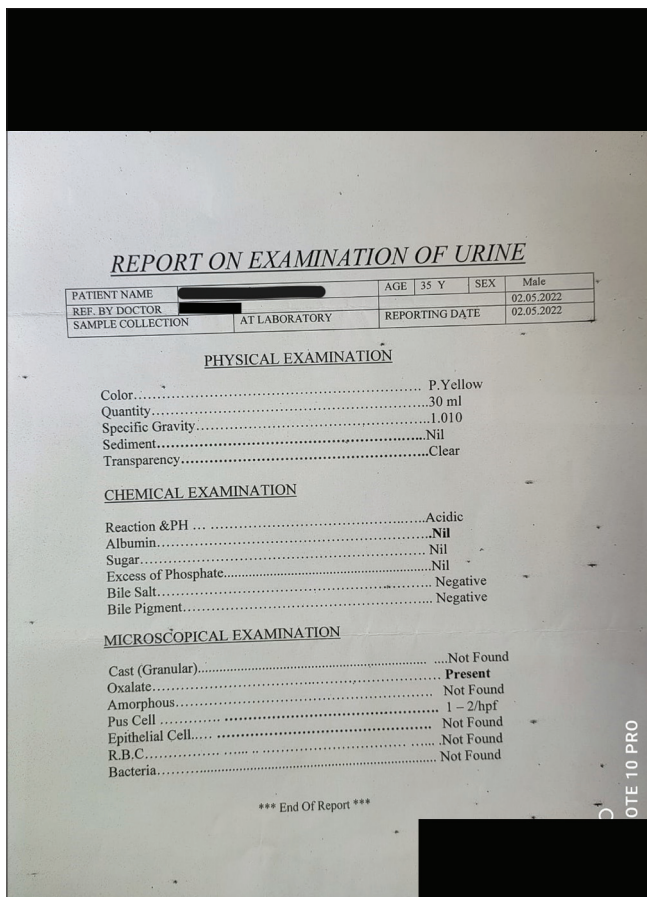


Figure 5: Urine report after treatment.

was done which shows no red cell in urine [Figure 5]. In one study, homoeopathic treatment was reported to be effective in renal calculi linked with fatty liver.^[14]

There have been several studies that demonstrate positive results in treating cases of renal calculi with homoeopathy.^[15-18] Even large urinary calculi (16.9 mm) have also been reported to be eliminated by homoeopathic treatment.^[19] The homoeopathic medicine, i.e. *Thuja*, was also found to be beneficial in the treatment of renal calculi.^[20]

The case was assessed using modified Naranjo criteria (MONARCH Inventory),^[21] which revealed a positive correlation between homoeopathic treatment and the outcome [Table 3].

The approach to managing renal calculi requires a personalised strategy. Evaluating symptoms, medical history, and test results aid in determining the necessity for immediate surgery or medical intervention. For clinically stable individuals with non-obstructive calculi, individuals who frequently develop calculi, and those with underlying systemic conditions, medical management is the recommended course of action.^[22] Homoeopathy is a simple system of medicine that focuses on addressing the person as a whole, considering both physical and emotional aspects for effective healing.

CONCLUSION

In this case, multiple renal calculi were present bilaterally and were treated efficiently with IHM. While homoeopathy offers

a potentially attractive alternative for managing renal calculi, the current scientific evidence is inconclusive. Further, high-quality research, including well-designed randomised controlled trials, is necessary to determine the true efficacy and safety of homoeopathic remedies in treating renal calculi.

Ethical approval

Institutional Review Board approval is not required.

Declaration of patient consent

Patient consent is not required as the patient's identity is not disclosed or compromised.

Financial support and sponsorship

Nil.

Conflicts of interest

There are no conflicts of interest.

Use of artificial intelligence (AI)-assisted technology for manuscript preparation

The authors confirm that there was no use of artificial intelligence (AI)-assisted technology for assisting in the writing or editing of the manuscript, and no images were manipulated using AI.

REFERENCES

- Asplin JR, Coe FL, Favus MJ. Disorders of the kidney and urinary tract- nephrolithiasis. In: Fauci AS, Braunwald E, Kasper DL, Hauser SL, Longo DL, Jameson JL, *et al.* editors. Harrison's principles of internal medicine. 17th ed. Vol. 2. New Delhi: McGraw-Hill Medical Publishing Division; 2008. p. 1815-7.
- Mohan H. The kidney and lower urinary tract. In: Textbook of pathology. 5th ed. New Delhi: Jaypee Brothers Medical Publishers Pvt Ltd.; 2008. p. 714.
- Leslie SW, Sajjad H, Murphy PB. Renal calculi. In: StatPearls. Treasure Island, FL: StatPearls Publishing; 2023.
- Alelign T, Petros B. Kidney stone disease: An update on current concepts. *Adv Urol* 2018;2018:3068365.
- Nhsinform.scot. Kidney stones; 2023. Available from: <https://www.nhsinform.scot/illnesses-and-conditions/kidneys-bladder-and-prostate/kidney-stones#treating-kidney-stones> [Last accessed on 2023 Aug 08].
- Urologyaustin.com. Small kidney stones; 2023. Available from: <https://urologyaustin.com/general-urology/small-kidney-stones> [Last accessed on 2023 Aug 08].
- Bhat MS. *Kidney. SRB's manual of surgery*. 4th ed. New Delhi: Jaypee Brothers Medical Publishers Pvt Ltd.; 2013. p. 1091.
- Siddiqui VA, Singh H, Gupta J, Nayak C, Singh V, Sinha MN, *et al.* A multicentre observational study to ascertain the role of homoeopathic therapy in urolithiasis. *Indian J Res Homoeopathy* 2011;5:30-9.
- International Classification of Diseases, Eleventh Revision (ICD-11), World Health Organization (WHO); 2019/2021. Available from: <https://icd.who.int/browse11> [Last accessed on 2023 Nov 01].
- Kent JT. *Repertory of the homoeopathic Materia Medica*. Uttar Pradesh: B Jain Publishers Pvt Ltd.; 2016.
- Bala R, Srivastava A. A review on history of LM potency: Tracing its roots in the past. *Int J Homoeopath Sci* 2019;3:26-31.
- Boericke W. *Pocket manual of homoeopathic materia medica with repertory*. 9th ed. Kolkata: Ghosh Homoeo Pharmacy; 2009. p. 409-510, 643-45.
- Teut M, Van Haselen RA, Rutten L, Lamba CD, Bleul G, Ulbrich-Zürni S. Case Reporting in homeopathy-an overview of guidelines and scientific tools. *Homeopathy* 2022;111:2-9.
- Vishwakarma A. A case report on fatty liver with renal calculi treated with homoeopathy. *Int J Homoeopath Sci* 2022;6:41-5.
- Suri MC. Scope of homoeopathy in treatment of renal calculi. *Int J Homoeopath Sci* 2021;5:246-50.
- Pandit RK, Pandey S. Individualized homeopathic approach in a case of multiple renal calculi. *AYUHOM* 2019;6:80-4.
- Sharma P, Aggarwal T, Subhamoy S. Management of urolithiasis with individualised homoeopathy-a case report. *Indian J Res Homoeopathy* 2021;15:263-9.
- Chakma A. Renal calculi: An evidence based case study. *Int J Med Allied Heal Sci* 2015;7:5-9.
- Gupta AK, Gupta J, Siddiqui VA, Mishra A. A big urinary calculus expelled with homoeopathic medicine. *Indian J Res Homoeopathy* 2008;2:50-5.
- Sonny R. Passage of calculus at lower pole of kidney facilitated by individualised homoeopathy: A case study. *Int J AYUSH Case Rep* 2022;6:121-7.
- Lamba CD, Gupta VK, Van Haselen R, Rutten L, Mahajan N, Molla AM, *et al.* Evaluation of the modified Naranjo Criteria for assessing causal attribution of clinical outcome to homeopathic intervention as presented in case reports. *Homeopathy* 2020;109:191-7.
- Barnela SR, Soni SS, Saboo SS, Bhansali AS. Medical management of renal stone. *Indian J Endocrinol Metab* 2012;16:236-9.

How to cite this article: Debnath N, Das K. An evidence-based case of bilateral nephrolithiasis treated with individualised homoeopathic medicine: A case report. *J Intgr Stand Homoeopathy*. doi: 10.25259/JISH_70_2023